



## EVALUATION OF N-ACETYL CYSTEINE WITH NANO-HYDROXYAPATITE BONE GRAFT FOR PRESERVATION OF ALVEOLAR RIDGE AFTER TEETH EXTRACTION

Sameh G. Abo Elkhier <sup>\*</sup>, Abdel magid Helmy El fakharany <sup>\*\*</sup>, Atef Mohamed Hassanen <sup>\*\*\*</sup>

### ABSTRACT

**Objective:** This study was designed to evaluate N-acetyl cysteine with Nano-hydroxyapatite bone graft for preservation of alveolar ridge after teeth extraction clinically and radiographically. **Subjects and methods:** Nano-hydroxyapatite bone graft and N-acetyl cysteine (NAC) were used to preserve sockets after extraction of badly decayed lower molars. To assess alveolar bone height, width and density, preoperative panorama and CBCT were done, immediately after extraction at 3 and at 6 months. **Results:** Regarding alveolar bone height and width, NAC showed the least decrease in lingual height, Nano-hydroxyapatite +NAC and NAC alone showed the higher increase in bottom and the least decrease in width measurements. Density measurements showed that Nano-hydroxyapatite + NAC and NAC alone showed the highest increase in density measurements. **Conclusion:** The use of NAC was safe and there were no complications and addition of NAC to Nano-hydroxyapatite resulted in marked enhancement of bone width.

**Keywords:** N-acetylcysteine, Socket Preservation, Bone Graft

### INTRODUCTION

Remodeling of hard and soft tissues observed after each tooth extraction, results in a dimensional shrinkage in both height and width of ridge. These changes depending on multiple variables including the alveolar socket size, the thickness of the mucosa, metabolic factors, and functional loading <sup>(1)</sup>. Both horizontal and vertical changes in dimensions are expected in hard tissue as well as soft tissue. Studies in the canine model <sup>(2)</sup> have demonstrated that there are marked dimensional changes of the alveolar ridge in the first 2–3 months post extraction, with the changes more pronounced on the buccal <sup>(3)</sup>. Attempt were performed to preserve the alveolar ridge for implant placement <sup>(4-6)</sup>. This preservation may be performed immediately after tooth extraction or in late stage <sup>(7)</sup>.

Immediate ridge preservation, is easy and resulted in greater oro-facial dimension of the bone <sup>(8)</sup>. Different types of biomaterials used for socket preservation including autogenous, allogeneic, xenogeneic, and alloplastic bone graft <sup>(9)</sup>, in addition to other materials such as platelet-rich plasma, fibrin and bone morphogenetic protein <sup>(10)</sup>. However, osteocompatibility of the bone substitute is crucial to the success of bone augmentation, due to oxidative stresses, and an adverse osteoblastic response. This may result in impairment of bone formation and prolongation of healing time <sup>(11)</sup>. N-acetyl cysteine (NAC) is an anti-oxidant amino acid derivative, which is an essential molecule in the intracellular reactive oxygen species (ROS) elimination system <sup>(12)</sup>. Its sulfhydryl group can directly scavenge free radicals and toxic compounds. The anti-oxidative

\* B.D.S, 2013 G Faculty of Dentistry Mansoura University

\*\* Professor, Department of Oral and Maxillofacial Surgery, Faculty of Dental Medicine, Boys, Cairo Al-Azhar University.

\*\*\* Ass. Professor, Department of Oral and Maxillofacial Surgery, faculty of Dental Medicine, Boys, Cairo Al-Azhar University.

function of NAC protects and prevents disruption of intracellular redox balance. This suggests that if collagenous bone graft materials negatively influence osteoblasts via oxidative stress, then NAC might improve their osteocompatibility (13,14).

**SUBJECTS AND METHODS**

Forty-four patients were selected from those attending Outpatient Clinics of Oral and Maxillofacial surgery, Department at faculty of Dental Medicine, Al-Azhar University, Boys, Cairo. Patients have badly broken unrestorable lower molar teeth, indicated for extraction.

**Clinical evaluation**

Complete history including; name, age, sex, occupation, residence, chief complaint, medical and dental history was taken from all patients. Intraoral examination was done to determine the condition of oral and periodontal health of the teeth to be extracted.

**Radiographic evaluation**

Digital panoramic radiograph and CBCT were done to evaluate; bone density, alveolar bone height at the site of extraction, Fig. (1).

**Surgical procedure**

Surgical procedure was done after achievement of local anesthesia according to group type. In all groups badly broken lower molar teeth were extracted as atraumatic as possible by means of periostomes and suitable forceps in attempting to preserve the osseous bone as much as possible. After tooth extraction, the socket was filled with NAC in the first group and NAC with bone graft in the second group, Fig. (2). In the third group, the socket was filled with bone graft only, while in the fourth group, control group, the socket closed without any materials or bone graft. Each group had 11 patients.

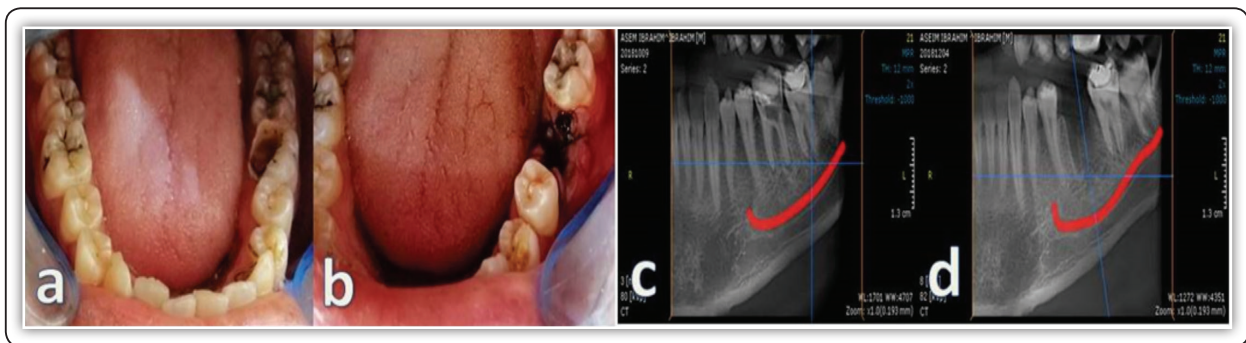


FIG (1) Photograph showing lower left decayed first molar(a) before, (b) after extraction,(c) digital panorama before and (d) digital panorama after with N acetyl cysteine in place.

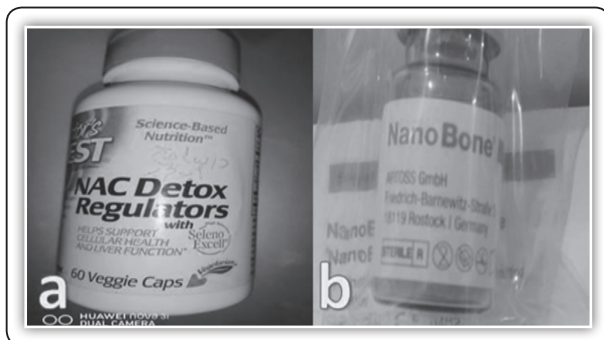


FIG (1) Photographs showing (a) NAC; and (b)Nanohydroxyapatite

**RESULTS**

Vertical bone height was assessed with CBCT to determine buccal and lingual bone height which measured from crestal alveolar height to inferior border of the mandible. Also, measurement was done from the bottom of the socket to the inferior border of the mandible. Horizontal measurement was done to determine width of bone. In addition, bone density was measured to determine the efficacy of synthetic bone with or with NAC on

bone formation. All measurements were done at mesial, middle and distal of the sockets and the average measurements were taken.

All patients had been examined periodically during the follow-up period up to 6 months. Healing was uneventful in all cases with no post-operative

complications. This was seen in the post-extraction radiographs, Fig.(3 and 4).

The average measurements of vertical bone height (buccal, lingual bone height and bottoms of the sockets) were decreased less than width measurements, Table (1 & 2)

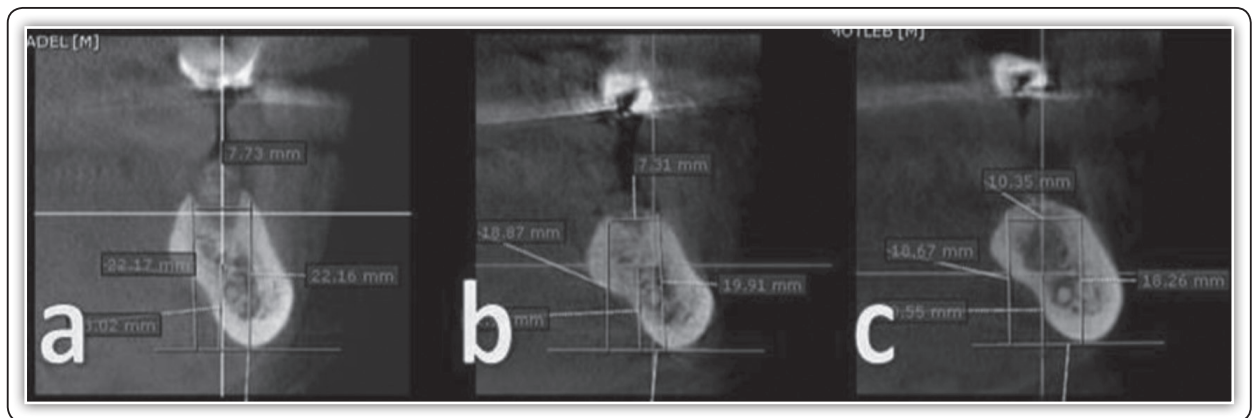


FIG (3) Coronal view CBCT of nanohydroxyapatite group of mesial side showing, measurements of vertical bone height (Buccal, lingual and bottom) and horizontal dimensions of the socket, immediately (a) and at 3 (b) and 6 months (c) after extraction.

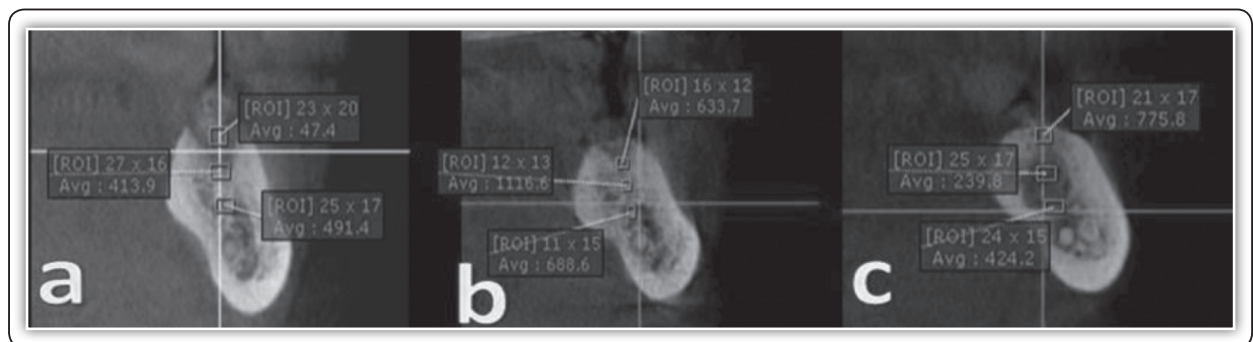


FIG (4) Coronal view CBCT of Nano-hydroxyapatite group of mesial side showing, measurements of bone density, immediately (a) and at 3 (b) and 6 months (c) after extraction.

**Table (1)** Showing buccal bone height in all groups at immediate, 3 & 6 months post extraction and differences between them

	Nano Hydroxyapatite (n = 11)	NAC (n = 11)	Nano Hydroxy .+ NAC (n = 11)	Control group (n = 11)	F	P
Height Buccal	Mean±SD	Mean±SD	Mean±SD	Mean±SD		
Baseline	21.68±1.97	21.69±1.78	20.26±0.39	22.15±3.29	0.742	0.543
3 months	20.12±0.44	20.75±1.84	19.66±0.60	20.73±2.41	1.984	0.157
6 months	19.87±0.22	19.91±1.75	19.34±0.86	19.09±2.07	1.360	0.291

**TABLE. (2)** Showing lingual bone height at immediate, 3 & 6 months post extraction in all groups and differences between them

	Nano Hydroxyapatite (n = 11)	NAC (n = 11)	Nano Hydroxy .+ NAC (n = 11)	Control group (n = 11)	F	P
Height lingual	Mean±SD	Mean±SD	Mean±SD	Mean±SD		
Baseline	23.27±1.47	22.72±1.97	19.92±0.34	24.92±1.16	0.876	0.643
3 months	20.32±0.45	21.85±2.04	18.47±0.57	22.05±1.24	8.803*	0.001*
6 months	19.65±0.44	20.90±2.06	18.17±0.67	20.37±0.64	5.341*	0.010*

NAC showed the least resorption in lingual height, also Nano-hydroxyapatite + NAC and NAC alone increased bone density measurements, table (3).

**TABLE (3)** Showing bone density measurements at immediate, 3 & 6 months post extraction in all groups and differences between them

	Nano Hydroxyapatite (n = 11)	NAC alone (n = 11)	Nano Hydroxy.+NAC (n = 11)	No Material (n = 11)	F	P
Density	Mean±SD	Mean±SD	Mean±SD	Mean±SD		
Baseline	410.7±36.43	402.2±105.9	420.4±70.97	404.1±164.5	3.294	0.021
3 months	491.0±54.49	495.9±21.99	575.6±52.57	515.5±55.87	3.231	0.051
6 months	619.6±151.7	748.4±37.71	768.4±26.50	639.5±23.55	4.410*	0.019*

## DISCUSSION

Based on the current state of knowledge, the initial post extraction resorption are a physiologic process that cannot be prevented. The only goal of socket preservation, is to minimize the defects and compensate for the remodeling processes that takes place.

Variety of materials is available for post-extraction ridge preservation. For optimal results, all grafts require an adequate blood supply, a form of mechanical support, and osteogenic cells supplied by the host, graft material, or both. Using Nano-hydroxyapatite as osteoconductive grafts act as a scaffold or lattice for the surrounding cells to infiltrate and migrate through the graft<sup>(15)</sup>.

The present study was to evaluate N-acetyl cysteine to enhance bone formation and bone height with Nano-hydroxyapatite after tooth extraction.

The findings of the present study that use NAC and NCHA as means of alveolar ridge preservation minimized ridge resorption in all dimensions, and that is in line with other findings recorded by Araujo and colleagues who studied dimensional ridge alterations following tooth extraction<sup>(16)</sup>. The average measurements of vertical bone height (buccal, lingual bone height and bottoms of the sockets) were decreased less than width measurements.

In Nano-hydroxyapatite + NAC and NAC alone showed the least decrease in width measurements. Nano-Hydroxyapatite + NAC and NAC alone showed the least decrease in bone height. With

agreement of our study, which resulted in a reduction of bucco-lingual width more than apicocoronal bone height, Schropp et al<sup>(17)</sup> reported the same results.

The findings of this study showed buccal bone height resorption was more than lingual bone height where NAC showed the least decrease in lingual bone height.

Nano-hydroxyapatite + NAC and NAC alone showed the highest increase in bone density measurements more than other groups in our study, at 6 months with statistically significant difference. Tadic and Epple,<sup>(18)</sup> reported that bone substitute has the inherent potential to induce oxidative stress, due to physicochemical treatment during manufacture, including deproteination and inactivation of pathogens.

This results was in contrary to McCormick<sup>(19)</sup> and Sanders<sup>(20)</sup>, they reported that oral administration of NAC haven't a pronounced effect in decreasing bone loss after menopause. Our result reported marked effect in decreasing bone loss which may be attributed to its local application

## CONCLUSIONS

1. The use of NAC was safe and there were no complications.
2. Addition of NAC to Nano-hydroxyapatite resulted in marked enhancement of bone width.
3. NAC showed the least resorption in lingual height, so it decrease bone resorption.
4. Nano-hydroxyapatite + NAC and NAC alone increased bone density measurements, in the present study.

## REFERENCES

1. Schropp, L., Wenzel, A., Kostopoulos, L. & Karring, T. Bone healing and soft tissue contour changes following single-tooth extraction: a clinical and radiographic 12-month prospective study. *Int J of Periodont & Restor Dent* 2003; 23: 313–23.
2. Araujo, M.G. & Lindhe, J. Dimensional ridge alterations following tooth extraction. An experimental study in the dog. *J of Clin Periodont* 2005; 32: 212–18.
3. Araujo, M.G., Sukekava, F., Wennstrom, J.L. & Lindhe, J. Ridge alterations following implant placement in fresh extraction sockets: an experimental study in the dog. *J of Clin Periodont* 2005; 32: 645–52.
4. Zhao J, Tsai C, Chang Y. Clinical and histologic evaluations of healing in an extraction socket filled with platelet-rich fibrin. *J Dent Scien (JDS)* 2011; 6:116-22.
5. Fee L. Socket preservation. *Br Dent J.* 2017; 21:579-82.
6. Maiorana C, Poli P, Deflorian M, Testori T, Mandelli F, Nagursky H, et al. Alveolar socket preservation with demineralised bovine bone mineral and a collagen matrix. *J Period Impl Sci* 2017; 47:194 -210.
7. Naineni R, Ravi V, Subbaraya D, Prasanna J, Panthula V, Koduganti R. Effect of Alendronate with  $\beta$  – TCP Bone Substitute in Surgical Therapy of Periodontal Intra-Osseous Defects: A Randomized Controlled Clinical Trial. *J Clin Diag Res* 2016; 10:113- 17.
8. Sarkar A ,Singhvi N , Jayaprasad N. Shetty , T. Ramakrishna, Shetye O. The Local Effect of Alendronate with Intra-alveolar Collagen Sponges on Post Extraction Alveolar ridge Resorption a Clinical trial. *J Oral Maxillofac Surg* 2015; 14:344-56.
9. Özer T, Akta A, Bari E, Çelik H, Vatanserver A. Effects of local alendronate administration on bone defect healing. Histomorphometric and radiological evaluation in a rabbit model. *Acta Cir Bras.* 2017; 32:781-95.
10. Guo J, Zhang Q, Li j, Liu Y, Hou Z, Wei Chen. Local application of an ibandronate/collagen sponge improves femoral fracture healing in ovariectomized rats. *Par Look Over Should* 2017; 12:1-22.
11. Ignjatovic N, Ninkov P, Kojic V, Bokurov M, Srdic V, Krnojelac D, et al. Cytotoxicity and fibroblast properties during in vitro test of biphasic calcium phosphate/poly-dl-lactide-co-glycolide biocomposites and different phosphate materials. *Microsc Res Tech* 2006; 69:976-82.
12. Schweikl, H., Spagnuolo, G. & Schmalz, G. Genetic and cellular toxicology of dental resin monomers. *J Dent Res* 2006; 85: 870–77.
13. Thibodeau, P.A., Kocsis-Bedard, S., Courteau, J., Niyonsenga, T. & Paquette, B. Thiols can either enhance or suppress DNA damage induction by catecholestrogens. *Free Radical Biology and Medicine* 2001; 30: 62–73.



14. Zafarullah, M., Li, Sylvester, J. Ahmad, M. Molecular mechanisms of N-acetylcysteine actions. *Cel Mol Life Sci* 2003; 60: 6–20.
15. Darby. Periodontal materials. *Aust Dent J.* 2011; 56: 107–18.
16. Cardaropoli G., M. Ara ´ujo, R. Hayacibara, F. Sukekava, and J. Lindhe. Dimensional ridge alterations following tooth extraction. An experimental study in the dog, *J Clin Periodontol*; 2005; 32: 212-14.
17. Schropp L., A.Wenzel, L. Kostopoulos, and T. Karring. Bone healing and soft tissue contour changes following singletooth extraction: a clinical and radiographic 12-month prospective study. *Int J of Periodontol and Restor Dent*, 2003; 23: 313–23.
18. Tadic D, Epple M. A thorough physicochemical characterisation of 14 calcium phosphate-based bone substitution materials in comparison to natural bone. *Biomater.* 2004; 25: 987-94.
19. McCormick, R. K. Osteoporosis: integrating biomarkers and other diagnostic correlates into the management of bone fragility. *Altern.Med Rev.* 2007;12:113-45.
20. Sanders, K. M., Kotowicz, M. A., and Nicholson, G. C. Potential role of the antioxidant N-acetylcysteine in slowing bone resorption in early post-menopausal women: a pilot study. *Transl.Res*2007;15: 1-15.