



AN IN VIVO STUDY ON THE DURABILITY OF RESIN INFILTRATION TECHNIQUE ON COLOR MASKING OF WHITE SPOT LESIONS

Ahmed Goda*, Khalid Noaman** and Belal Saleh**

ABSTRACT

The caries infiltration technique was introduced with the aim of filling the intercrystalline spaces with a low-viscosity resin, to arrest lesions and treat the esthetic problem of white spot lesions. This study was designed to evaluate the color effect and durability of resin infiltration technique on masking of enamel white spot lesions compared to an ordinary adhesive system. **Methods:** a total number of 20 patients having 120 not cavitated anterior teeth with white spot lesions were subjected to this study. The six maxillary anterior teeth were isolated with rubber dam. The teeth were divided into two groups, the first group (central incisor, lateral incisor and canine on right side of patient) was treated with hydrochloric acid (Icon-Etch) then ethanol (Icon-Dry) followed with application of resin (Icon-Infiltrate), while the second group: (central incisor, lateral incisor and canine on left side of the same patient) was treated with phosphoric acid (N-Etch) and adhesive (Excite F). Evaluation of color was done using VITA Easyshade V (VITA Germany) at the following intervals (pre-operative, immediate, one week, three months, six months and twelve months post-operatively). **Results:** the highest mean value of color change was found immediately post-operatively for icon resin infiltration group presented as positive (ΔL) and negative (ΔC) that means decrease in the whitish discoloration of teeth. **Conclusions:** Icon resin infiltration is an effective treatment for demineralized white spot lesions, while Excite F adhesive can be used for short time sealing of enamel surface to improve the esthetics of white spot lesions.

INTRODUCTION

Opaque white spots on the facial surfaces of the teeth can be an unsightly appearance. The whitish appearance is due to the presence of internal porosities beneath an apparently intact surface layer that alters the refractive index of usually translucent enamel⁽¹⁾.

The caries infiltration technique was introduced with the aim of filling the intercrystalline spaces with a low-viscosity resin, to arrest lesions^(2,3). The caries infiltration technique is a promising therapeutic method as its approach is between preventive and restorative actions in the treatment of noncavitated carious lesions⁽⁴⁾. The infiltration technique has gained a lot of interest in the past few years. It is less invasive than microabrasion and restorative treatments⁽⁵⁾.

The application of adhesive for sealing the susceptible enamel surface in order to form a caries-protective shield (specially prior to bracket bonding) has been the focus of interest in previous studies^(6,7).

The aim of this study was to compare the effect of resin infiltrate versus dental adhesive on color masking of white spot lesions, and to extend available knowledge on the longevity of achieved color and lightness improvement of both materials for twelve months' period.

Ethical considerations:

Full ethical approval was obtained from Faculty of Dental Medicine, Boys, Cairo, Al-Azhar University Ethics Committee, and all patients were given informed consent before the beginning of the study.

* Assistant lecturer of Operative Dentistry Department, Faculty of Dental Medicine, Assuit, Al-Azhar University

** Professor of Operative Dentistry Department, Faculty of Dental Medicine, Boys, Cairo, Al-Azhar University

MATERIALS AND METHODS

Two resin based materials were utilized in this study:

1. Icon resin infiltration: It comprised 3 steps for resin infiltration; icon etch, icon dry and icon infiltrant.(DMG America, Englewood USA)

2. ExciTE F dental adhesive: It was a two-step etch and rinse adhesive. It comprised 2 steps N-Etch and ExciTE F adhesive (Ivoclar Vivadent).

Methods:

This study was a follow-up of patients with White spot lesions treated by two resin infiltration techniques during a single-center, split-mouth trial.

1. Patients selection:

A total of 20 adult Egyptian patients agreed to participate in the current study, those were selected from the outpatient clinics, Operative Dentistry Department, Faculty of Dental Medicine, Assuit, Al-Azhar University

1.a. Inclusion criteria:

1. Obvious area of white spot lesions on labial surface of maxillary anterior teeth.
2. Non-cavitated enamel surface.
3. Maxillary anterior teeth were free of any restorations.
4. No history of tooth sensitivity or previous whitening procedures.

1.b. Exclusion criteria:

1. Cavitated enamel surface that requiring restoration.
2. Presence of any restorations including the labial surface of the maxillary anterior teeth.
3. Presence of any environmental or developmental enamel defect.
4. Smoking, para-functional habits or gingivitis.

A signed informed consent was obtained from every participant.

2. Study design:

A total number of twenty patients having a total number one hundred and twenty anterior teeth with white spot lesions (not cavitated) were subjected to this study. Teeth were divided according to type of infiltrating materials into two main groups A1 and A2 (60 teeth each). The infiltrated teeth of each group were evaluated at different durations; B0, B1, B2, B3, B4, and B5.

3. Intervention:

All teeth were scaled and polished with fluoride-free polishing paste using polishing brush, the color of white spot areas was measured as a control using clinical spectrophotometer (VITA EasysshadeV, Zahnfabrik, Germany) with infection control shield (Figure 1).

After rubber dam isolation of the maxillary anterior teeth with premolar clamps on first premolar teeth. A 15% HCl gel (Icon-Etch) was applied on the labial surface of first group (A1) for 120 seconds (Figure 2).

The etchant was rinsed off with water spray for at least 30 seconds, a 99% ethanol (Icon-Dry) was applied onto the etched area for 30 seconds, after which it was air dried. Then the resin infiltrate was applied onto the etched lesion surface and left for 180 seconds to infiltrate and spread into the micro-porosities and then light-cured (output of 450 nm wavelength and a light intensity of 800 mW/cm² for 40 seconds). A second layer of Icon-Infiltrant was applied, for 60 seconds, and light-cured again for 40 seconds.

Phosphoric acid gel (N-Etch) was applied for 20 seconds on labial surface of teeth of second group (A2) (Figure 3) then rinsed off with water for 10 seconds then it was air dried for 10 seconds using air syringe.

Excite F adhesive was then applied and rubbed in for 20 seconds with a micro-brush and light cured for 20 seconds, a second layer of adhesive was applied as the first one. immediate post-operative color evaluation was done using VITA Easy-shade V as described before, and the detailed color information was recorded.

4. Post-operative aging and follow up:

At every follow up visit, anterior teeth were polished with fluoride-free polishing paste using a rubber cup. The maxillary six anterior teeth were isolated with cotton rolls and air-dried for 5 seconds. Then, color of the treated white spot areas were measured for the color change evaluation using VITA Easy-shade V as described before.

5. Data management and statistical analysis:

Both (ΔL) and (ΔC) were calculated as the difference between L and C respectively at each time interval as compared to base line values (pre-operative), The mean and standard deviation values were calculated for each group in each test. Data were explored for normality using Kolmogorov-Smirnov and Shapiro-Wilk tests. Data showed non-parametric (not-normal) distribution. Friedman test was used to compare between more than two related samples. While Mann Whitney test was used to compare between two non-related samples, Wilcoxon test was used to compare between two related samples.

The significance level was set at $p \leq 0.05$. Statistical analysis was performed with IBM® SPSS® Statistics Version 20 for Windows.

RESULTS

For color evaluation both of (ΔL) and (ΔC) values were calculated as the difference between L and C respectively at each time interval as compared to base line values (pre-operatively).

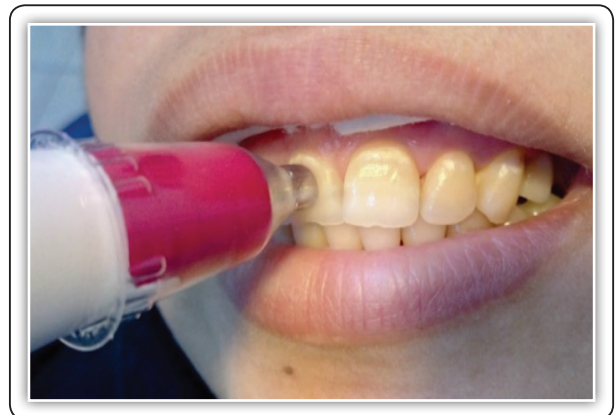

Fig. (1) Using Vita Easyshade V with infection control shield

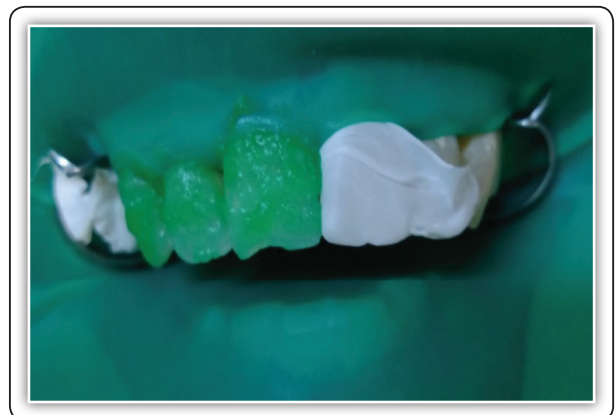

Fig. (2) Application of icon etch

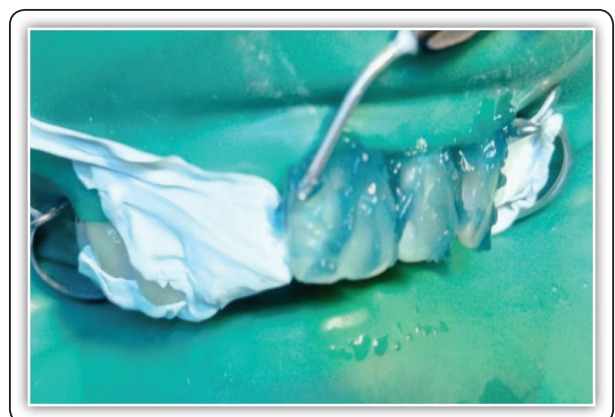

Fig. (3) Application of N etch

Effect of time and materials on color change (ΔL)

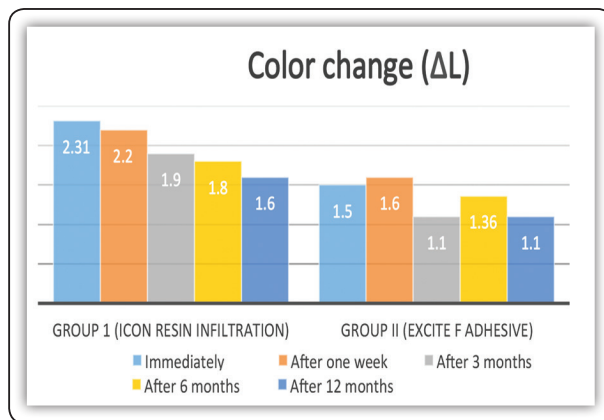


Fig. (4) Bar chart representing the effect of time and material on color change ΔL .

DISCUSSION

White spot lesions disturb the esthetic appearance of the enamel of the front teeth⁽⁸⁾, and also they are an initial stage of enamel caries that can progress to a stage at which restoration will be needed if the patient has inadequate oral hygiene⁽⁹⁾. So there are two aspects of treating white spot lesions considering: arresting lesion progression, and addressing the esthetic disturbance⁽⁸⁾.

White spot lesions show irregular mineralization patterns and are histologically characterized by highly porous hypomineralized subsurface enamel⁽¹⁰⁾. The removal of the surface layer may enable access to the volume of porous enamel, which could be penetrated by a resin with a refractive index (RI) similar to sound enamel afterwards. Adapting the RI of the lesion to the RI of enamel would allow masking of the subsurface enamel alteration. The objective of infiltration in esthetic areas is thus to fill up the microporosities of hypomineralized enamel with a resin whose RI is close to that of healthy enamel, in order to mask the enamel defect⁽²⁾

Icon resin infiltration (DMG) is an innovative product for the micro-invasive treatment of cervical

Effect of aging time and materials on color evaluation (ΔC)

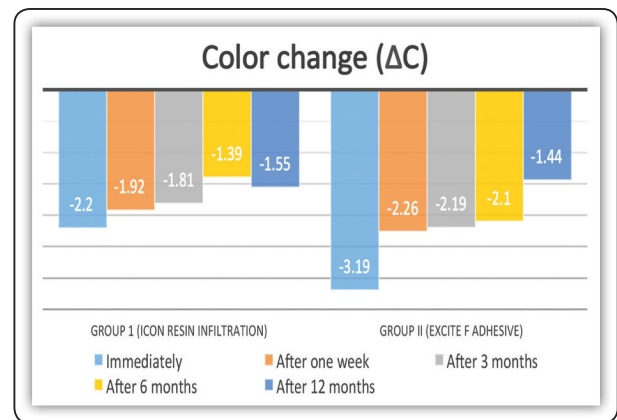


Fig. (5) Bar chart representing the effect of aging and materials time on color change ΔC .

and proximal dental lesions. Driven by capillary forces, the infiltrant, a highly fluid resin, penetrates into the enamel caries and blocks the diffusion paths for cariogenic acids, thus promoting the early arrest of caries. Icon closes the gap between preventive therapies and corrective restorations.

Excite F dental adhesive is one of the commonly used etch and rinse dental adhesives, it is a fluoride releasing, Acetone free, high monomer content, light-curing single-component dentin enamel adhesive.

VITA Easy-shade V represents the color in LCH formula. The LCH expression offers an advantage over CIELAB in that it's very easy to relate to the earlier systems based on physical samples, like the Munsell color scale. The Munsell system assigns numerical values to the three properties of color: hue, value and chroma, because it is based on human perception. CIELCH uses polar coordinates. The L defines lightness, C specifies chroma and H denotes hue angle, an angular measurement⁽¹¹⁾.

ΔL = difference in lightness/darkness (value)+ = lighter – = darker
 ΔC = difference in chroma+ = brighter – = duller (less chromatic, or less saturated).

ΔH = difference in hue (color itself as green, yellow, red, etc)

Because no colored materials used in the study we used both (ΔL) and (ΔC) for color evaluation; values were calculated as the difference between L and C respectively at each time interval as compared to base line values (pre-operative)

The results revealed that the highest mean value of color change is found immediately post-operative for icon resin infiltration group presented as positive (ΔL) and negative (ΔC) that means decrease in the whitish discoloration of teeth, this result is agreed with many authors⁽¹²⁻¹⁶⁾. This esthetic improvement slightly deteriorates with time but still sufficient over 12 months, this result is in agreement with Torres et al⁽¹⁵⁾ who studied icon resin infiltration for eight weeks and showed that it was proven to be an effective treatment for masking white spot lesions, while Knoeslet al⁽¹³⁾ who showed that Icon infiltration improves the esthetic appearance of demineralized teeth with sufficient durability over 6 months. Eckstein et al⁽¹⁷⁾ showed that esthetic camouflage effects achieved by infiltration were not altered significantly after 12 months.

Also, the highest mean value of color change in the Excite F adhesive group was found immediately post-operative presented as positive (ΔL) and negative (ΔC) that means effective decrease in the whitish discoloration of teeth, this result is in agreement with Kantovitz et al (2014)⁽¹⁸⁾ and Paris et al⁽¹⁹⁾.

CONCLUSION

Icon resin infiltration is an effective treatment for demineralized white spot lesions, while Excite F adhesive can be used for short time sealing of enamel surface to improve the esthetics of white spot lesions.

REFERENCES

1. Shivanna V, Shivakumar B. Novel treatment of white spot lesions: A report of two cases. *J Conserv Dent*. 2011 Oct; 14(4):423-6.
2. Paris S, Meyer-Lueckel H, Cölfen H, Kielbassa AM. Resin infiltration of artificial enamel caries lesions with experimental light curing resins. *Dent Mater J*. 2007 Jul;26(4):582-8.
3. Meyer-Lueckel H, Paris S. Improved resin infiltration of natural caries lesions. *J Dent Res*. 2008 Dec;87(12): 1112-6.
4. Kielbassa AM, Muller J, Gernhardt CR. Closing the gap between oral hygiene and minimally invasive dentistry: a review on the resin infiltration technique of incipient (proximal) enamel lesions. *Quintessence Int*. 2009 Sep;40(8):663-81.
5. Kim S, Kim EY, Jeong TS, Kim JW. The evaluation of resin infiltration for masking labial enamel white spot lesions. *Int J Paediatr Dent*. 2011 Jul;21(4):241-8.
6. Schmidlin PR, Schätzle M, Fischer J, Attin T. Bonding of brackets using a caries-protective adhesive patch. *J Dent*. 2008 Feb;36(2):125-9.
7. Paschos E, Kleinschrodt T, Clementino-Luedemann T, Huth KC, Hickel R, et al. Effect of different bonding agents on prevention of enamel demineralization around orthodontic brackets. *Am J Orthod Dentofac Orthop*. 2009 May;135(5):603-12.
8. Knösel M, Attin R, Becker K, Attin T. External bleaching effect on the color and luminosity of inactive white-spot lesions after fixed orthodontic appliances. *Angle Orthod*. 2007 Jul;77(4):646-52.
9. Featherstone JD. The science and practice of caries prevention. *J Am Dent Assoc* 2000; 131:887-99.
10. Bronckers AL, Lyaruu DM, DenBesten PK. The impact of fluoride on ameloblasts and the mechanisms of enamel fluorosis. *J Dent Res*. 2009 Oct;88(10):877-93.
11. Sikri VK. Color: Implications in dentistry. *J Conserv Dent*. 2010 Oct;13(4):249-55
12. Hammad SM, El Banna M, El Zayat I, Mohsen MA. Effect of resin infiltration on white spot lesions after debonding orthodontic brackets. *Am J Dent*. 2012 Feb;25(1):3-8.
13. Knösel M, Eckstein A, Helms HJ. Durability of esthetic improvement following Icon resin infiltration of multibracket-induced white spot lesions compared with no therapy over 6 months: a single-center, split-mouth, randomized clinical trial. *Am J Orthod Dentofac Orthop*. 2013 Jul;144(1):86-96.

14. Kugel G, Arsenault P, Papas A. Treatment modalities for caries management, including a new resin infiltration system. *CompendContinEduc Dent.* 2009 Oct;30 Spec No 3:1-10; quiz 11-2.
15. Torres C, Borges AB, Torres LM, Gomes IS, de Oliveira RS. Effect of caries infiltration technique and fluoride therapy on the color masking of white spot lesions. *J Dent.* 2011 Mar;39(3):202-7.
16. Yuan H, Li J, Chen L, Cheng L, Cannon RD, Mei L. Esthetic comparison of white-spot lesion treatment modalities using spectrometry and fluorescence. *Angle Orthod.* 2014 Mar;84(2):343-9.
17. Eckstein A, Helms HJ, Knösel M. Camouflage effects following resin infiltration of postorthodontic white-spot lesions in vivo: One-year follow-up. *Angle Orthod.* 2015 May;85(3):374-80.
18. Borges A, Caneppele T, Luz M, Pucci C, Torres C. Color stability of resin used for caries infiltration after exposure to different staining solutions. *Oper Dent.* 2014 Jul-Aug;39(4):433-40.
19. Paris S, Meyer-Lueckel H, Mueller J, Hummel M, Kielbassa AM. Progression of sealed initial bovine enamel lesions under demineralizing conditions in vitro. *Caries Res.* 2006;40(2):124-9.